

ORIGINAL ARTICLE



Adenosquamous Carcinoma of Distal Bile Duct with Pancreatic Metastasis : A Case Report

Yaoping Pang¹, Yanhong Shi¹, Yuesheng Li, Shulin Xu, Baiwen Miao^{*}, Jianwei Qin^{*}

Department of Hepatobiliary Surgery, The 940th Hospital of Joint Logistics Support Force, Chinese People's Liberation Army, Lanzhou, Gansu, 730050, China

Corresponding Author: Baiwen Miao, Jianwei Qin

Abstract

This paper reports a rare case of adenosquamous carcinoma of the distal bile duct in a 69-year-old male patient. The patient visited the hospital due to jaundiced skin and sclera, and was diagnosed as adenosquamous carcinoma (lower common bile duct) after operation. Postoperative S-1 monotherapy was effective, and no tumor recurrence or metastasis was observed during follow-up. Distal bile duct adenosquamous carcinoma is characterized by strong invasion, easy recurrence and metastasis, and poor prognosis. Timely surgery and postoperative adjuvant therapy are essential to improve the prognosis. This case reflects the clinical characteristics and treatment status of the disease, which is of certain value to clinical practice.

Key words Distal bile duct adenosquamous carcinoma; Surgical treatment; Chemotherapy; Prognosis

Introduction

Cholangiocarcinoma is a malignancy originating from the biliary system, which can be classified into intrahepatic and extrahepatic cholangiocarcinoma based on its location. Distal cholangiocarcinoma refers to cancer located in the lower segment of the common bile duct. Due to its unique location, early symptoms are often subtle, and the disease is frequently diagnosed at an advanced stage, presenting significant challenges for treatment. Adenosquamous carcinoma, a rare histological subtype, combines characteristics of both adenocarcinoma and squamous cell carcinoma. It is highly malignant with a poor prognosis¹². This article presents a case of distal bile duct adenosquamous carcinoma with pancreatic metastasis, aiming to raise awareness among clinicians about this rare tumor and to explore related issues concerning its diagnosis, treatment, and prognosis. The uniqueness of this case lies not only in the rarity of the tumor type but also in the occurrence of pancreatic metastasis, which further complicates the treatment.

Through a detailed analysis of this case, we hope to provide a reference for clinicians handling similar cases, promote further research into distal bile duct adenosquamous carcinoma, and ultimately improve patient survival rates and quality of life. Additionally, this case serves as a reminder to maintain a high level of vigilance when dealing with biliary tract tumors and to carry out early, accurate diagnosis and appropriate treatment planning.

Clinical Data

The patient is a 69-year-old male who was admitted on May 25, 2022, due to jaundice of the skin and sclera for over 20 days. Over 20 days prior to admission, he noticed yellowing of the skin and sclera, dark-colored urine resembling strong tea, and clay-colored stool. He reported no abdominal pain or bloating, no nausea or vomiting, no fever or chills, and no acid reflux or belching. He had experienced a weight loss of approximately 5 kg over the past month. His

medical history includes an appendectomy performed 10 years ago due to "suppurative appendicitis." Ten days before admission, he underwent surgery for "anal fistula" at a local hospital, during which elevated blood glucose levels were noted, and he was subsequently diagnosed with "diabetes." Personal history reveals a 30-year smoking habit of 10-20 cigarettes per day and a 30-year history of drinking white liquor, approximately 250 ml per day.

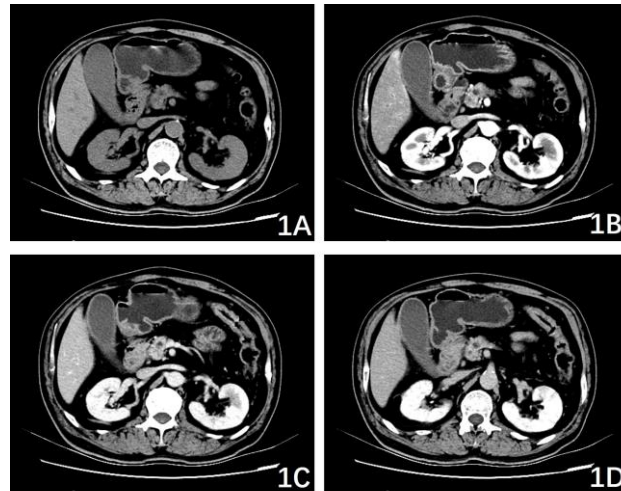
Upon admission, the physical examination revealed severe jaundice of the skin and sclera, with a flat abdomen. No tenderness, muscle rigidity, or rebound tenderness were noted upon abdominal palpation. No significant positive signs were found in other organs, including the heart and lungs. Laboratory tests showed: white blood cell count of $12.15 \times 10^9/L$, neutrophil percentage of 73.7%, procalcitonin of 0.213 ng/ml, carbohydrate antigen 19-9 (CA19-9) of 44.2 U/mL, total bilirubin of 288.80 $\mu\text{mol/L}$, direct bilirubin of 268.30 $\mu\text{mol/L}$, aspartate aminotransferase (AST) of 80 IU/L, alanine aminotransferase (ALT) of 152 IU/L, alkaline phosphatase of 430 IU/L, gamma-glutamyl transferase (GGT) of 514.00 IU/L, and serum albumin of 33.5 g/L. Abdominal CT of the upper abdomen revealed enlargement of the pancreatic hook region, with a nodular soft tissue density mass, well-defined borders, measuring approximately 2.9 cm \times 2.1 cm. On contrast-enhanced scans, the mass showed mild to moderate enhancement. The intra- and extrahepatic bile ducts, along with the main pancreatic duct, were significantly dilated. Atrophy of the pancreatic body and tail was noted, with invasion into the medial wall of the duodenum, suggesting a diagnosis of ampullary carcinoma (Figure 1).

After admission, the patient underwent percutaneous transhepatic cholangial drainage under ultrasound guidance, with a catheter placed in the right hepatic duct. In addition, the patient received treatments for infection control and liver protection. Following active management, the bile drainage became unobstructed, and serum bilirubin levels gradually decreased to near-normal levels. The patient was scheduled for pancreaticoduodenectomy.

Intraoperatively, the pancreas was found to be enlarged and firm, with multiple nodules in the pancreatic body and tail, raising the possibility of tumor metastasis. A nodule from the pancreatic body was excised and sent for rapid frozen section, which revealed adenocarcinoma. Further exploration revealed tumor invasion into the left gastric artery, making dissection challenging. Therefore, a decision was made to perform total pancreatectomy, total gastrectomy, choledochojejunostomy, esophagojejunostomy, and jejunojejunostomy.

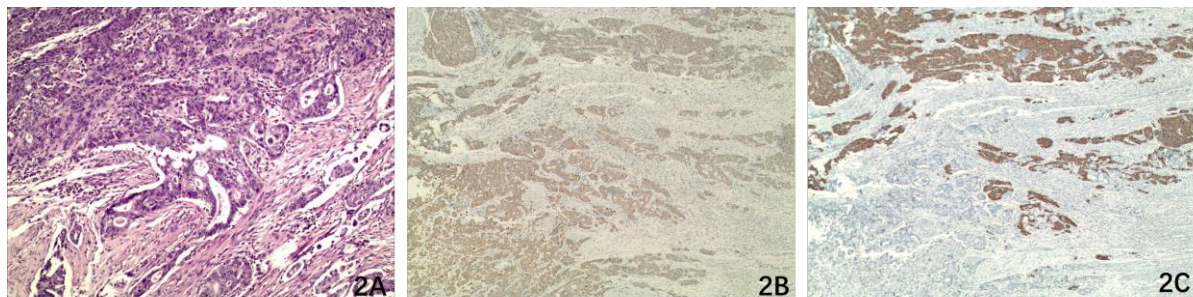
Postoperative pathological diagnosis: (distal common bile duct) adenosquamous carcinoma. The cancer tissue invaded the pancreas and surrounding adipose tissue, with tumor thrombus formation in the blood vessels. No cancer tissue was found at the bile duct resection margin. Lymph node metastasis was present in 6 of 21 lymph nodes, with no metastasis in the gastric lymph nodes (0/5), pancreaticoduodenal lymph nodes (6/10), group 9 lymph nodes (0/2), group 12 lymph nodes (0/3), and mesenteric lymph nodes (0/1). Immunohistochemical results: CA19-9 partial (+), CerbB-2 (0), CK19 (+), CK5/6 (+), TP63 (+), Ki67 \approx 60% (Figure 2). The re-examination of the pancreatic nodular lesion intraoperatively was consistent with adenosquamous carcinoma.

The patient had a favorable postoperative recovery. Insulin replacement therapy was initially administered through a regular insulin micro-pump and transitioned to subcutaneous injections of insulin aspart and insulin detemir. Blood glucose levels were well controlled, and no severe complications such as bile leakage or intestinal fistula occurred. It was recommended that the patient undergo chemotherapy with "gemcitabine + tegafur," but both the patient and family declined. As a result, oral monotherapy with "tegafur" was initiated one month after surgery (50 mg bid on days 1–28 of each cycle, repeated every 6 weeks). Follow-up examinations at one month, two months, five months, one year, and two years postoperatively revealed no recurrence or metastasis of the tumor. Relevant tumor markers and other tests showed no abnormal elevations. The patient is currently under ongoing surveillance.



1A Plain scan phase; 1B. Arterial phase; 1C. Venous phase; 1D. Delay period

Figure 1 Preoperative upper abdominal CT scan of a patient with distal bile duct adenosquamous carcinoma



2A. Mixed components of adenocarcinoma and squamous cell carcinoma were observed (HE staining $\times 100$). 2B. CK5/6 positive (IHC $\times 40$); 2C. CK19 was positive (IHC $\times 40$).

Figure 2 Postoperative pathological results of patients with distal bile duct adenosquamous carcinoma

Discussion

Adenosquamous carcinoma is a malignant tumor composed of both adenocarcinoma and squamous carcinoma components in varying proportions. It is commonly found in the lungs, prostate, breast, gastrointestinal tract, and pancreas, and may also occur in organs with a relatively high incidence of squamous cell carcinoma, such as the esophagus¹⁻². Cholangiocarcinomas are predominantly adenocarcinomas, with squamous carcinomas being rare, and adenosquamous carcinoma is even more uncommon. Reports suggest it is more frequently observed in male patients³. Extrahepatic cholangiocarcinoma with adenosquamous histology accounts for 3.0%-4.7% of all extrahepatic bile duct cancers¹. The precise pathogenesis and etiology of cholangiocarcinoma with adenosquamous differentiation remain unclear. Currently, it is hypothesized that tumor stem cells possess the potential to differentiate

into both squamous and adenocarcinoma components, with mixed differentiation products resulting in adenosquamous carcinoma. Additionally, adenosquamous carcinoma is considered a transitional stage in the progression of adenocarcinoma to squamous carcinoma, and simultaneous occurrence of both adenocarcinoma and squamous carcinoma within the bile duct is also proposed⁴. Microscopically, cholangiocarcinoma with adenosquamous differentiation exhibits both adenocarcinoma and squamous carcinoma components, along with transitional areas between the two⁵. The adenocarcinoma component typically contains mucus-secreting cells and various-sized glandular structures, while the squamous carcinoma component is characterized by keratin pearls arranged in nests, accompanied by eosinophilic, transparent cytoplasm and intercellular bridges⁶⁻⁷. Immunohistochemically, the adenocarcinoma component often expresses CK7, CK18, and

CK19, while the squamous carcinoma component is typically positive for CK5/6, P40, and P63⁸. In the pathology images of this case, both adenocarcinoma and squamous carcinoma components, as well as their interface, are visible. Immunohistochemistry shows CK5/6 positivity for the squamous cell carcinoma component, negative for adenocarcinoma, and both squamous carcinoma and adenocarcinoma components are positive for CK19, with stronger expression in the adenocarcinoma component.

Adenosquamous carcinoma typically exhibits an infiltrative growth pattern, often directly invading surrounding organs and blood vessels, and is frequently associated with lymph node metastasis⁹. Intrahepatic metastasis and lymph node involvement are major prognostic factors, usually appearing shortly after surgery. The average survival time for cholangiocarcinoma with adenosquamous differentiation is 7.5 to 8.6 months, with the majority of patients succumbing within one year¹⁰⁻¹¹. There are currently no specific treatment guidelines or consensus for cholangiocarcinoma with adenosquamous differentiation, though early radical surgical resection has been shown to prolong survival. In this case, the patient was found to have pancreatic metastases during surgery, which was confirmed by intraoperative frozen pathology, and there was also tumor invasion of the left gastric artery. Given the extensive nature of the surgical resection, the patient's prognosis requires further follow-up and observation. Voong reported that adjuvant chemoradiotherapy after surgery significantly improves overall survival in cases of pancreatic adenosquamous carcinoma¹², and some studies have indicated that postoperative treatment with "tegafur" showed no recurrence of the tumor after six months, although overall efficacy remains uncertain¹³. In this case, the patient opted for monotherapy with "tegafur" postoperatively, and at one month of follow-up, no recurrence of the tumor has been observed. Additionally, there are reports suggesting that in advanced-stage tumor patients who are no longer candidates for curative surgery, treatment with "gemcitabine and oxaliplatin" may yield some degree of effectiveness¹⁴.

Conclusion

In summary, cholangiocarcinoma with adenosquamous differentiation is a rare and highly

invasive malignant tumor of the bile ducts, with a worse prognosis compared to pure cholangiocarcinoma. Its prognosis is associated with tumor invasiveness and the presence of squamous tissue. Clinical presentation and imaging studies are non-specific, and a definitive diagnosis relies on pathological confirmation. Early radical surgical resection may be beneficial in prolonging survival, though recurrence and metastasis often occur in the early postoperative period, and the efficacy of adjuvant therapy remains to be further validated. In this case, the cholangiocarcinoma with adenosquamous differentiation presented with multiple pancreatic metastases and vascular invasion, leading to the performance of total pancreatectomy and total gastrectomy. Long-term outcomes require further observation and evaluation.

Funding

This work was supported by the Natural Science Foundation of Gansu Province (22JR5RA014).

Data availability statements

The data generated in the present study may be requested from the corresponding author. (E-mail: qinjianwei940@163.com)

The data generated in the present study are included in the figures and/or tables of this article.

Authors' contributions

PYP and SYH analyzed the data and were the primary author of the manuscript. They are the co-first authors of this article. XSL acquired the CT scan images. LYS analyzed patient data. MBW confirm the authenticity of the data. QJW assisted in writing the manuscript. All authors have read and approved the final manuscript.

Patient consent for publication

Written informed consent was obtained from the patient for the publication of this case report and any accompanying images.

Competing interests

The authors declare that they have no competing interests.

References

1. Qin BD, Jiao XD, Yuan LY, et al. Adenosquamous carcinoma of the bile

- duct: a population-based study[J]. *Cancer Manag Res.* **2018**,10:439-446.
2. Patel P, Trivedi P. Adenosquamous carcinoma of ampulla of Vater-a case report with review of literature[J]. *J Gastrointest Cancer.* **2016**, 47(4):446-448.
 3. Duan JC, Li MF, Yang JH, et al. Diagnosis and Treatment of Intrahepatic Cholangiocarcinoma with Squamous and Adenosquamous Differentiation (Including Five Case Reports and Literature Review) [J]. *Journal of Hepatobiliary Surgery*, **2014**, 22(05): 399-400.
 4. Li C, Lu H. Adenosquamous carcinoma of the lung[J]. *Onco Targets Ther.* **2018**,11:4829-4835.
 5. Dong W, Liu L, He JN, et al. Clinical Analysis of Two Cases of Primary Hepatic Adenosquamous Carcinoma [J]. *Chinese Journal of Hepatobiliary Surgery*, **2016**, 22 (12): 3.
 6. Yamao K, Takenaka M, Imai H, et al. Primary Hepatic Adenosquamous Carcinoma Associated with Primary Sclerosing Cholangitis[J]. *Oncology.* **2017**;93 Suppl 1:76-80.
 7. Li B, Zhang Y, Chen S, et al. (18)F-FDG PET/CT in a case of primary hepatic adenosquamous carcinoma[J]. *Rev Esp Med Nucl Imagen Mol.* **2016**,35(5):344-346.
 8. Maeda T, Takenaka K, Taguchi K, et al. Adenosquamous carcinoma of the liver: clinicopathologic characteristics and cytokeratin profile[J]. *Cancer.* **1997**;80(3):364-371.
 9. Ren ZY, Lü SC, Cao D, et al. Diagnostic and Therapeutic Analysis of Eight Cases of Distal Cholangiocarcinoma with Adenosquamous Differentiation [J]. *Chinese Journal of General Surgery*, **2021**, 36(10): 2.
 10. Gao S, Chen D, Huang L, et al. Primary adenosquamous carcinoma of the liver: a case report and review of the literature[J]. *Int J Clin Exp Pathol.* **2015**;8(8):9687-9692.
 11. Qin L, E CY, Wu Q. A Case Report of Cholangiocarcinoma with Adenosquamous Differentiation [J]. *Chinese Journal of Laboratory Diagnosis*, **2021**, 25(09): 1401-1402.
 12. Voong KR, Davison J, Pawlik TM, et al. Resected pancreatic adenosquamous carcinoma: clinicopathologic review and evaluation of adjuvant chemotherapy and radiation in 38 patients[J]. *Hum Pathol.* **2010**; 41(1):113-122.
 13. Hong SM, Kim MJ, Jang KT, et al. Adenosquamous carcinoma of extrahepatic bile duct: clinicopathologic study of 12 cases [J]. *Int J Clin Exp Pathol.* **2008**;1(2):147-156.
 14. Valle J, Wasan H, Palmer DH, et al. Cisplatin plus gemcitabine versus gemcitabine for biliary tract cancer[J]. *N Engl J Med.* **2010**;362 (14): 1273-1281.